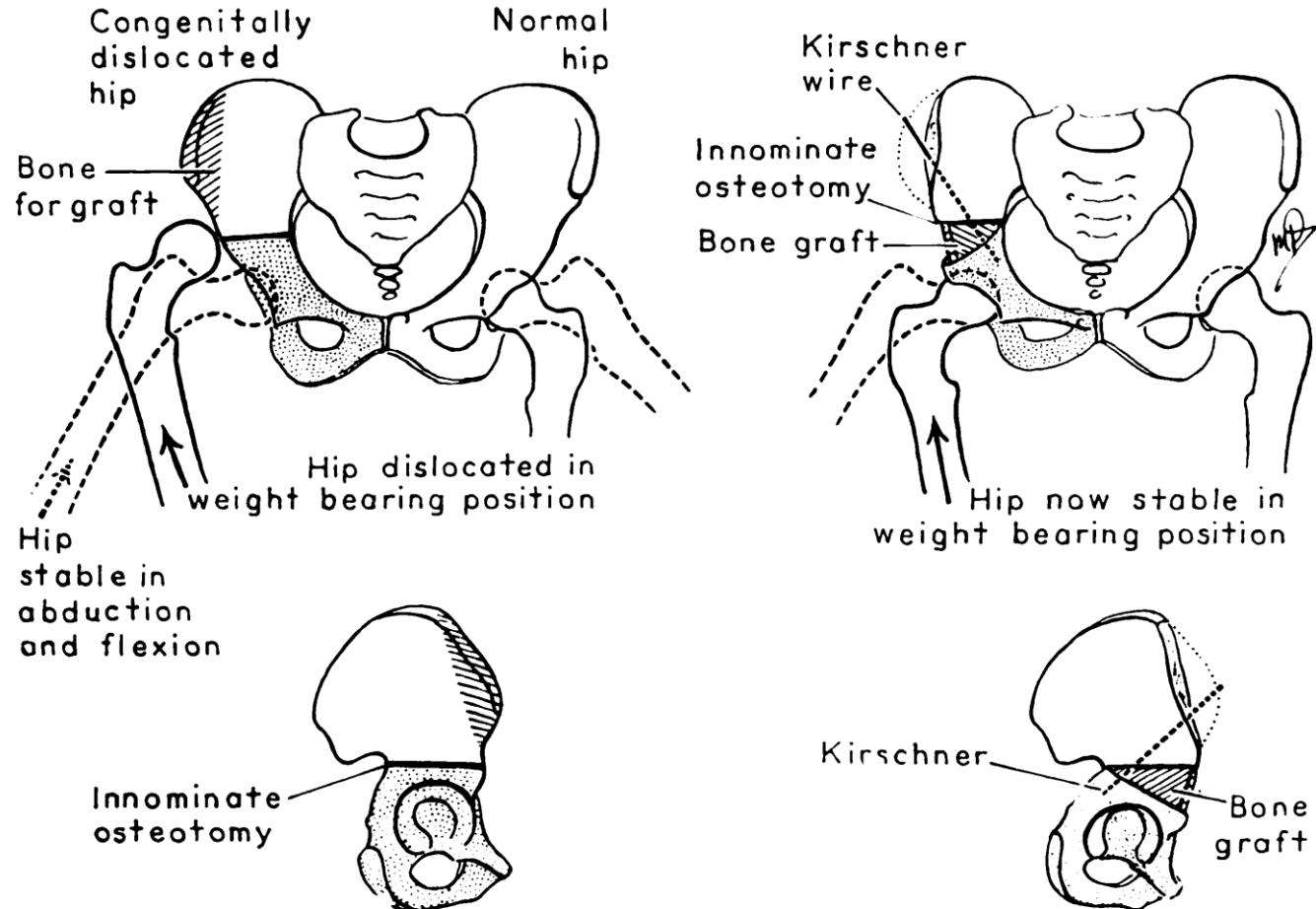


# Salter osteotomy

Dr Tero Laine

Östra Sjukhuset, Gothenburg

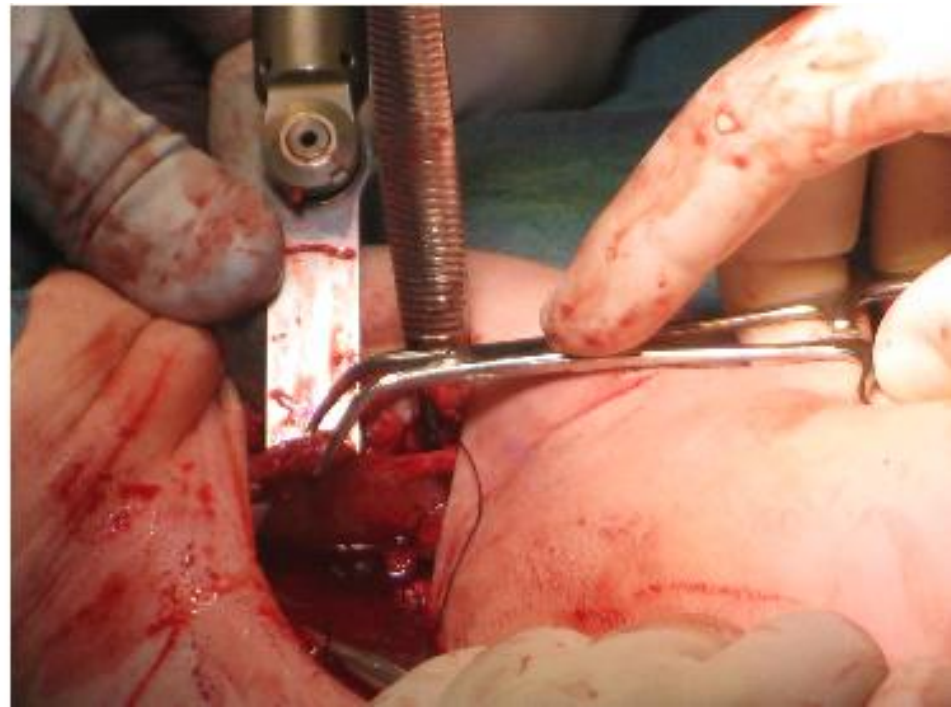
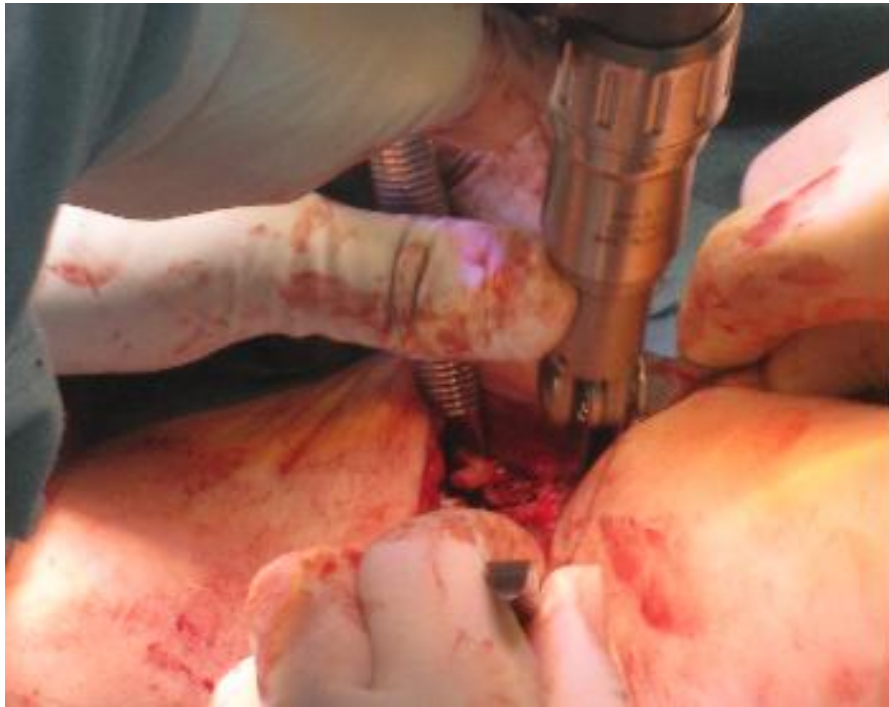
# Introduction



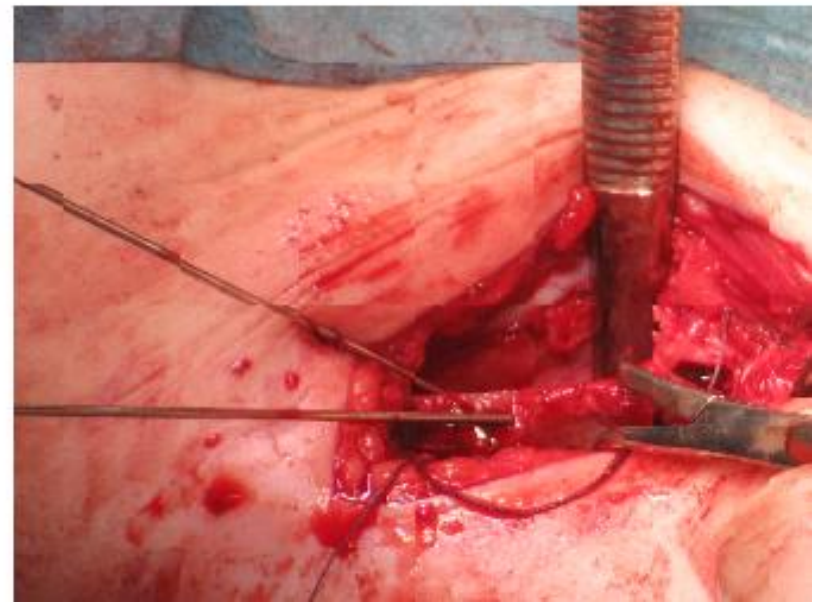
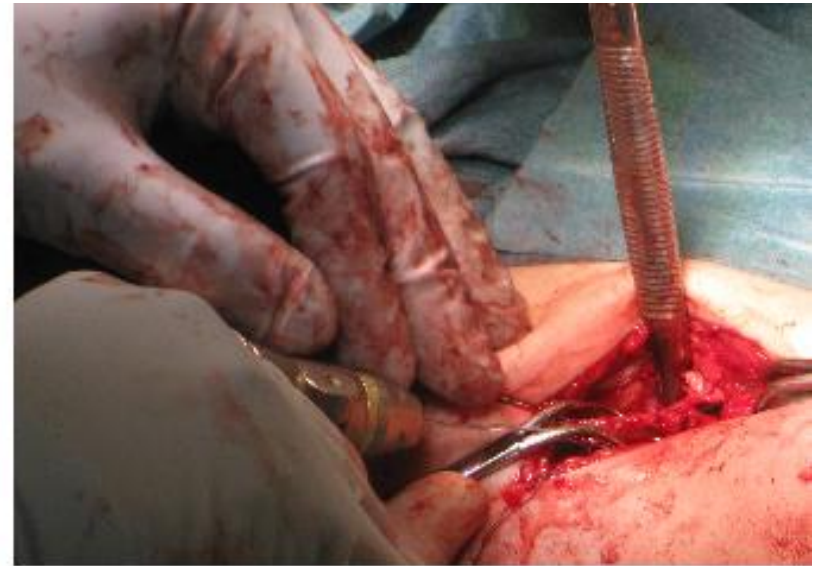
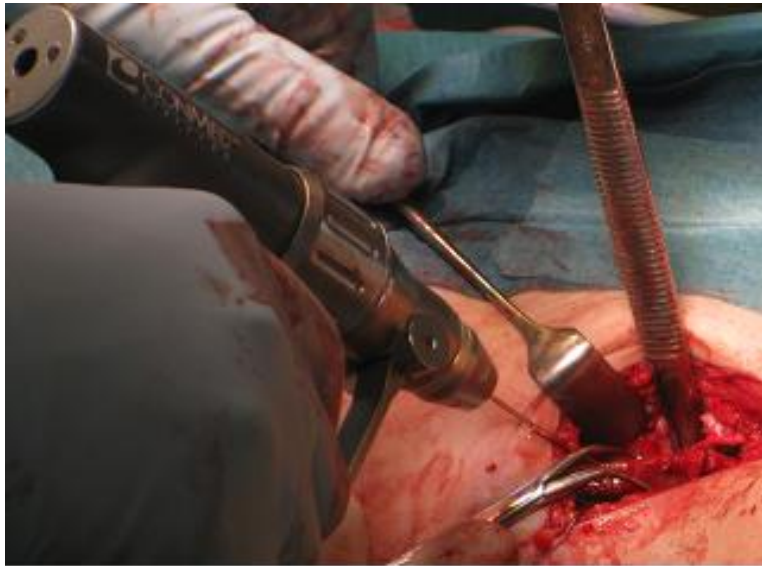
# Case description

- 3 years old child with congenital dislocation of the hip
- Salter osteotomy performed using two fully threaded 4.5mm ActivaScrew™ Cannulated.

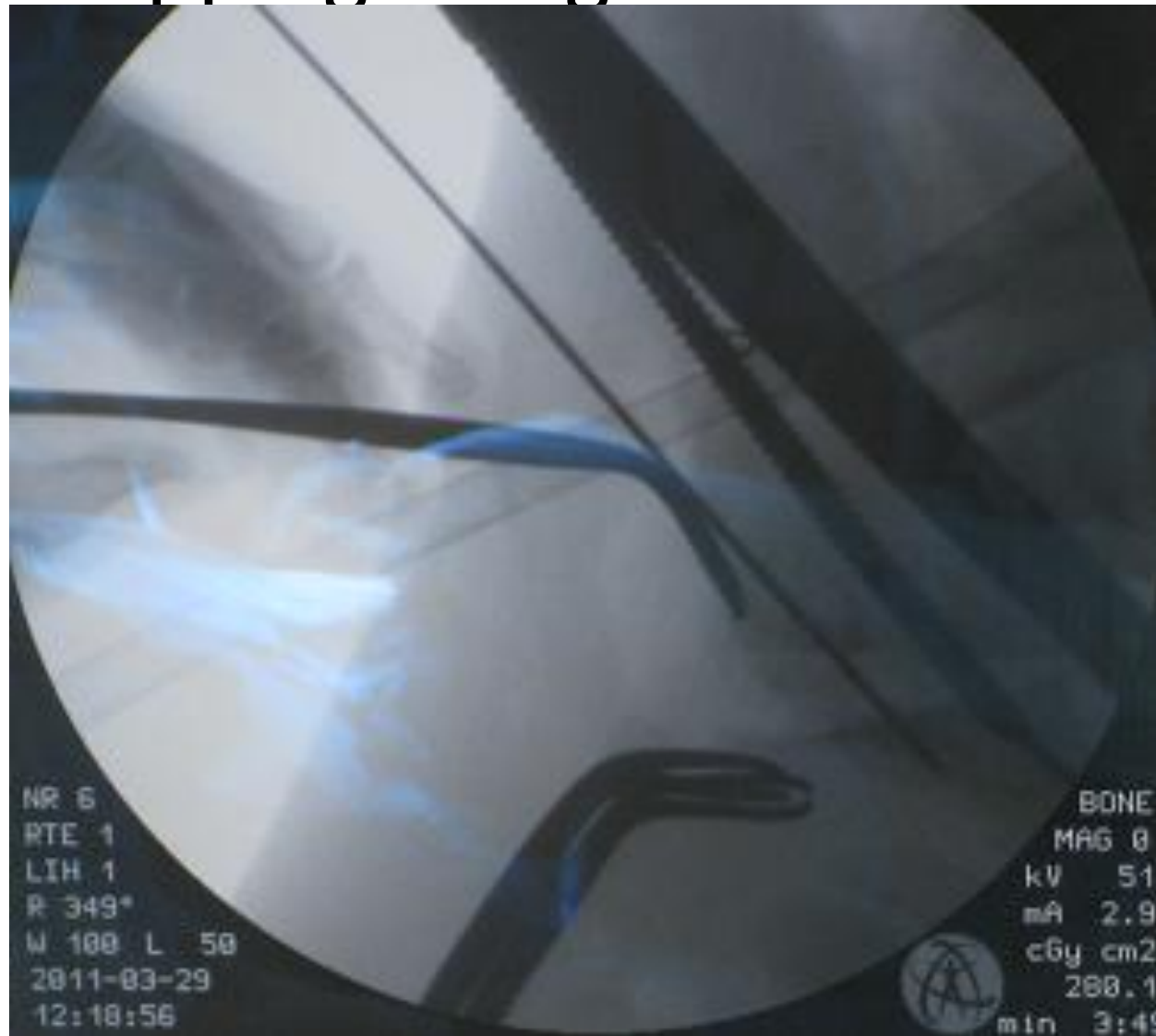
# Surgical procedure- osteotomy and autograft



# Surgical procedure - K-wires in position



# Surgical procedure – tapping along the K-wire



# Surgical procedure –inserting the screw

